



The Effect of Tadalafil on Anastomotic Healing in Rats, Which Have a Small Intestinal Ischemia Reperfusion

Lütfi Mutlu¹, Ramazan Serdar Arslan^{2*}, Semra Tutcu Şahin³, Yavuz Kaya³,
Teoman Coşkun³ and Eray Kara³

¹Department of General Surgery, Tepecik Training and Research Hospital, Health Sciences University, Izmir, Turkey.

²Department of General Surgery, Usak Training and Research Hospital, Usak, Turkey.

³Department of General Surgery, Faculty of Medicine, Celal Bayar University, Manisa, Turkey.

Authors' contributions

This work was carried out in collaboration among all authors. Author LM designed the study, performed the statistical analysis, wrote the protocol and wrote the first draft of the manuscript. Authors RSA and STS managed the analyses of the study. Authors YK, TC and EK managed the literature searches. All authors read and approved the final manuscript.

Article Information

Editor(s):

(1) Dr. Kaushik Bhattacharya, CAPFs Composite Hospital Border Security Force, India.

Reviewers:

(1) Fleres Francesco, Sondrio Hospital, Italy.

(2) Hakim Athar, Faculty of Veterinary Sciences and Animal Husbandry, India.

Complete Peer review History: <http://www.sdiarticle4.com/review-history/60902>

Original Research Article

Received 02 July 2020
Accepted 07 September 2020
Published 16 September 2020

ABSTRACT

Background/Aim: To investigate the effect of specific phosphodiesterase 5 inhibitor on anastomotic healing in rat small intestine which was an ischemia reperfusion injury.

Materials and Methods: 48 male Sprague-Dawley rats divided into four equal groups (n = 12). Standardized transection, a full cut was made approximately 15 centimeters proximal to the cecum and anastomosis were performed to the tips of bowel. Group 1, normal anastomosis; group 2, normal anastomosis + tadalafil treatment; group 3, intestinal anastomosis was performed after 30 minutes of intestinal ischemia and reperfusion; group 4, intestinal anastomosis was performed after 30 minutes of intestinal ischemia and reperfusion + tadalafil treatment. Postoperative 4th day anastomosis bursting pressure, tissue hydroxyproline level, and histopathologically anastomosis evaluation were assessed by modified Ehrlich-Hunt scoring.

*Corresponding author: E-mail: r.arslan@saglik.gov.tr, r.serdar.arslan@gmail.com;

Results: The use of Tadalafil in ischemia and reperfusion groups was found to significantly increase the burst pressures. There was a statistically significant difference in hydroxyproline concentration between all groups. There was no statistically significant difference between the groups in histological evaluation in terms of inflammatory cell infiltration, vascular reaction and anastomotic collagen deposition.

Conclusion: Although tadalafil cannot be shown histopathologically, it was concluded that it has positive effects on recovery of small intestine anastomosis after reperfusion of intestinal ischemia.

Keywords: Tadalafil; ischemia; anastomosis; reperfusion; hydroxyproline; burst pressure.

1. INTRODUCTION

For general surgeons, the most feared complication in the perioperative period is anastomotic leakage (AL) and intra-abdominal fecal contamination. AL still remains in the first place among the factors responsible for mortality and morbidity after gastrointestinal system surgery [1-3]. A combination of local and systemic factors is required for a good anastomosis healing. Perfusion and oxygenation of anastomosis are the most important of these factors [4-6]. Small bowel ischemia and reperfusion can disrupt anastomosis healing, causing an AL [3-6]. Ischemia reperfusion (IR) of the small intestine is seen in clinical practice such as bleeding, trauma, mesenteric vascular disease, and in surgical procedures where the arteries are temporarily clamped [4-7]. Reperfusion is the elimination of the factor that causes ischemia and the restore of blood flow to the tissue [7,8]. Reperfusion has two positive effects, such as providing the energy needs in ischemic tissue and removing toxic metabolites. Reperfusion is a necessary process to correct ischemic injury [9,10].

However, the return of oxygenated blood to ischemic tissue initiates a reaction process that further damages the tissue [9-12]. IR injury occurs with a complex mechanism accompanied by free oxygen radicals, endothelial factors and neutrophils [8-12]. The event that triggered the damage is thought to be the damage to the endothelial cells [10-12]. One of the important protective agents created by endothelial cells in IR is nitric oxide (NO) [8-13]. NO has protective effects from IR injury, such as immune defense, reduction of oxygen radicals, inhibition of leukocyte adhesion, reduction of vascular permeability and vasodilation [10-13]. Tadalafil is a specific, selective and potent inhibitor of phosphodiesterase enzyme type-5 (FDE-5). Tadalafil is currently used for the treatment of erectile dysfunction [14,15]. PDE-5 was commonly detected in the vascular system,

mesenteric artery, pulmonary artery, saphenous vein [16-18]. Tadalafil prolongs the effects of NO by inhibition of PDE-5 [14-18]. In this study, we aimed to investigate the effect of Tadalafil on small bowel anastomosis healing in rats with intestinal IR.

2. MATERIALS AND METHODS

2.1 Ethics and Animals

Sprague-Dawley type rats of male breed, average weight of 250 grams, obtained from Experimental Animals Laboratory of Ege University Faculty of Medicine were used. They were brought to the laboratory 10 days before the study, allowing them to adapt to the working environment. The rats were kept in wire cages at room temperature, 12 hours of light and 12 hours of darkness. They were spontaneously Fed as much standard rat feed and tap water as they could get.

2.2 Surgical Procedures

The animals were anesthetized by intramuscular injection of 50 mg/kg ketamine hydrochloride (Ketalar, Parke-Davis, Eczacıbaşı, Istanbul, Turkey) and 5 mg/kg xylazine hydrochloride (Rompun, Bayer, Istanbul, Turkey) [6,7]. The procedures were performed between 09.00 - 12.00 hours in order to prevent the rats from being affected by diurnal hormonal changes. The skin was surgically prepared with 10% povidone iodine. A midline laparotomy was performed under general anesthesia. Intestinal ischemia and reperfusion were performed according to the technique described by Megison et al. [7]. Arteria mesenterica superior was dissected from the aorta to the exit site and clamped just below the middle colic artery branch. Collateral arteries from the arteria colica dextra and proximal jejunal arteries at the doudenojejunal junction were clamped simultaneously with the superior mesenteric artery to create absolute small bowel ischemia.

After 30 minutes of ischemia, all clamps were opened. The small intestine was transected 15 cm proximal to the ileocecal valve and a standardized end-to-end anastomosis was performed with inverting 6-0 polydioxanon (B. Braun Melsungen AG 8714827, Germany) sutures using the single-layer technique. 40 ml/kg 0.9% NaCl solution was administered to the peritoneal cavity before the laparotomy incision was closed, taking into account the hypovolemic effects of fluid loss during surgical procedures. Laparotomy incision was closed with continuous 3/0 silk sutures in two layers with peritoneal fascia and skin apart.

2.3 Experimental Groups and Protocol

Rats divided into four equal groups (n = 12). Group 1, normal anastomosis; group 2, normal anastomosis + tadalafil treatment; group 3, intestinal anastomosis was performed after 30 minutes of intestinal ischemia and reperfusion; group 4, intestinal anastomosis was performed after 30 minutes of intestinal ischemia and reperfusion +tadalafil treatment. The first and third groups were given 1 ml of saline via orogastric tube for four days starting 2 hours before the operation. The second and fourth groups were given 10 mg/kg/day of Tadalafil (Cialis; Lilly del Caribe, Carolina, Puerto Rico) in 1 ml of saline for four days starting 2 hours before the operation, and through the orogastric tube. Rats were sacrificed on the fourth day postoperative. No complications such as necrosis, AL, abscess, peritonitis, bleeding were detected in rats. Intestinal adhesions were dissected carefully to prevent injuries in the anastomotic site and bowel. Nearly 6 cm segment of intestine with the anastomosis in the middle was resected and washed in saline. The effect of tadalafil on anastomotic healing was evaluated by hydroxyproline concentration, bursting pressure and a histopathological evaluation of the anastomotic site.

2.4 Measurement of the Bursting Pressure

Mechanical evaluation of anastomosis healing was evaluated by anastomosis burst pressure measurement [19,20]. A standard bowel length was obtained by cutting the bowel segment over two centimeters proximal and distal of the anastomosis line. The proximal end of the bowel segment was used to measure pressure, while the distal end was used to give fluid. Distal end of the resected small intestinal segment was

ligated around a catheter connected to an infusion pump (Abbott®LC 5000 infusor, Abbott Lab Abbert Park, IL). The proximal end was ligated around a pressure transducer connected to a monitor (Power Lab ML845 4/25 Data Recording System, MLT0380/A Reusable Blood Pressure Transducer; AD Instruments, Bella Vista, NSW, Australia). Intraluminal pressure changes were monitored while saline was pumped into the lumen at a rate of 2 ml/min. Bursting pressure was recorded (in units of mm Hg) reached before evident saline leakage or sudden loss of pressure. After that one cm segment of the intestine with the anastomosis line in the middle was excised and longitudinally divided into two equal pieces for histopathological evaluation, measurement of hydroxyproline concentration.

2.5 Measurement of Hydroxyproline

The prepared homogenate was read on spectrophotometer at 550 NM. Hydroxyproline levels in the samples were calculated according to the standard curve-absorbance graph (mg/g) [21].

2.6 Histopathological Evaluation

Tissue samples belonging to anastomosis were taken in paraffin blocks following a routine histochemical procedure. The four micrometre sections were stained with haematoxylin-eosin. Sections were examined in a blinded fashion under a light microscope (Olympus CH 30) x 400) by an expert pathologist. Anastomosis wound healing was scored with histopathologically modified Ehrlich and Hunt scoring [22,23].

2.7 Statistical Analysis

Statistical evaluations were performed using the "SPSS 10.0 for Windows" package program (SPSS Inc, Chicago, IL, ABD). Group averages and standard deviation were evaluated by one way analysis and Anova variance analysis was used to determine whether there was a significant difference between groups in general. Turkey HSD test was used to compare groups with each other. P value <0.05 were considered statistically significant.

3. RESULTS

The distribution of the anastomosis bursting pressures and pressure averages of the rats in

all groups is given in Figs. 1 and 2. A significant difference was found between all groups by ANOVA test (p:0,000). The highest mean anastomosis bursting pressure was obtained in group 2, where Anastomosis + Tadalafil was administered to the normal intestine (56.75 mm Hg). Anastomoses in normal bowel without Tadalafil (group I) were obtained with lower bursting pressures compared to Group II (39.42 mm Hg). However, no statistical significance was found (p:0.24). The mean anastomosis burst pressure was 50.58 mm Hg in the group group IV) that used Tadalafil after IR, while only 29.08 mm Hg was found in the group (group III) that did not use Tadalafil. Tadalafil use was found to significantly increase bursting pressures after IR (p:0,003).

The distribution of hydroxyproline levels in all groups is shown in Fig. 3 and group averages are shown in Fig. 4. There was statistically

significant difference between all groups (p:0.001). The highest hydroxyproline levels were in Group II (average of 15.65 mg/g). Hydroxyproline levels in Group I were 12.08 mg/g on average. There was no statistically significant difference between group 1 and group 2 (p:0.084). In the groups that were anastomosed after IR, an average age of 14.39 mg/g was found in those who were given Tadalafil (group IV), but in group III, which was not given Tadalafil, it was found to be 9.61 mg/g. Tadalafil administration was found to increase anastomosis hydroxyproline levels statistically significantly after IR (p: 0,011). Bursting pressure, hydroxyproline levels and statistical evaluation results are given in Table 1.

In histopathological evaluation, there were no statistically significant differences in collagen deposition, inflammatory cell infiltration, vascular reaction (Fig. 5).

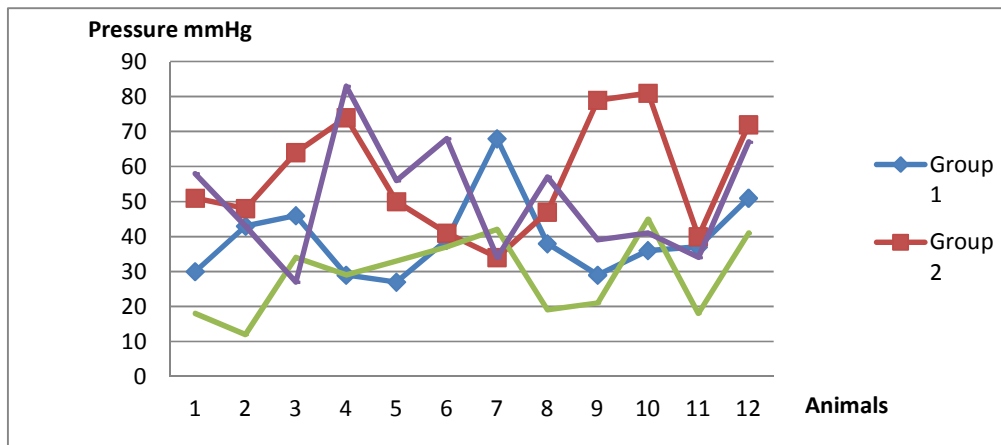


Fig. 1. Bursting pressure distributions by groups

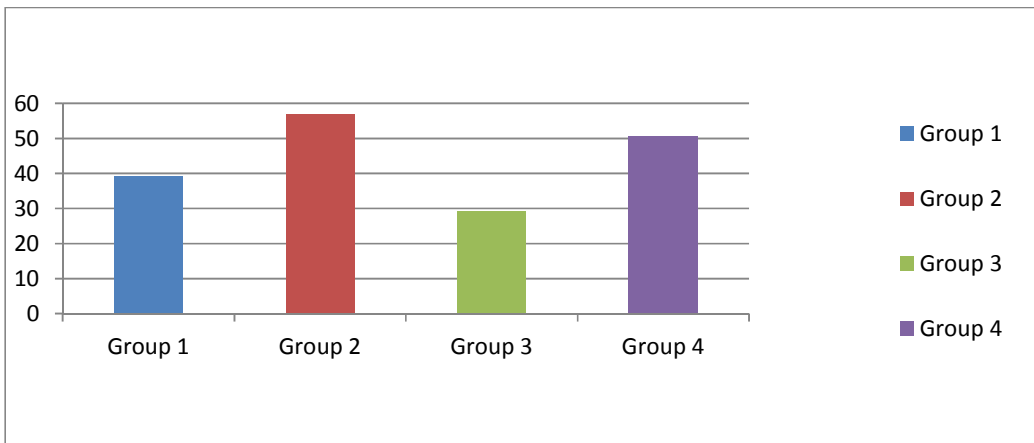


Fig. 2. Anastomosis bursting pressure averages

Table 1. Bursting pressure, hydroxyproline levels and statistical evaluation results

	Averages of groups and standard deviations				p values					
	Group 1	Group 2	Group 3	Group 4	Group 1	Group 2	Group 3	Group 4	Group 3	Group 4
	Group 1	Group 2	Group 3	Group 4	Group 2	Group 3	Group 4	Group 3	Group 4	Gorup 4
BP	39.42±3.36	56.75±4.74	29.08±3.22	50.58±4.38	0.024	0.299	0.24	0.000	0.716	0.003
HP	12.08±1.59	15.65±0.82	9.61±0.30	14.39±0.98	0.084	0.345	0.399	0.001	0.825	0.011

BP: Bursting pressure, HP: Hydroxyproline levels

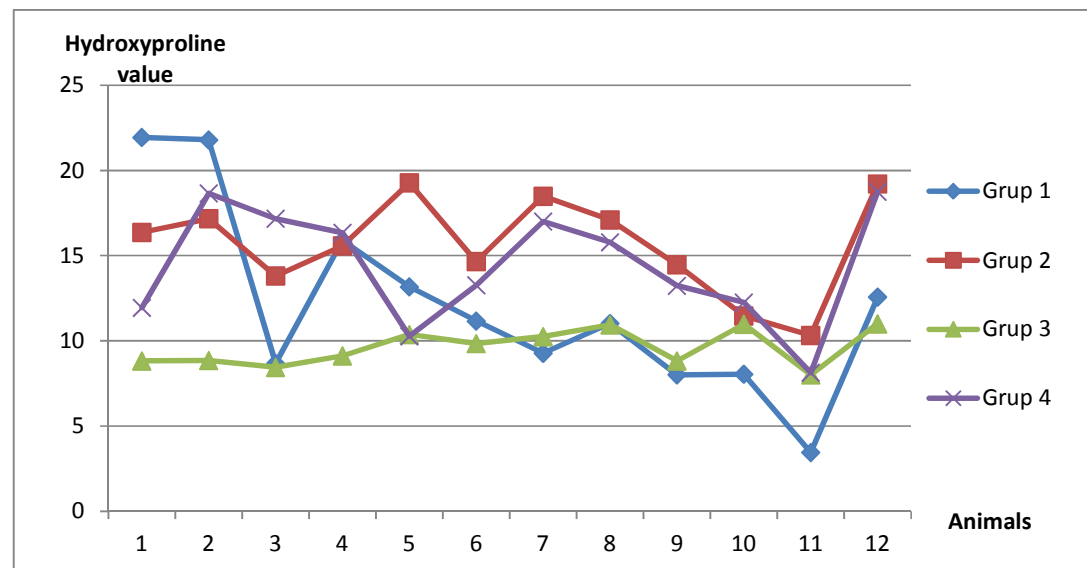


Fig. 3. Distribution of hydroxyproline values by groups

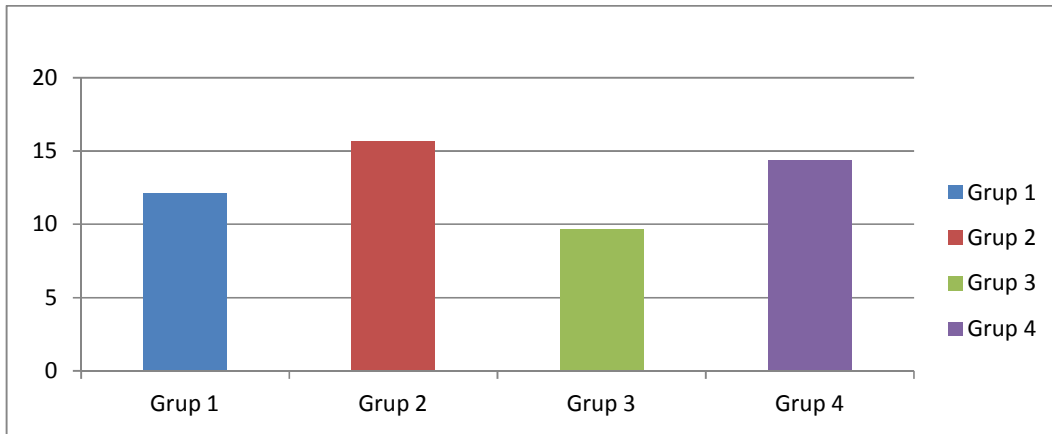


Fig. 4. Hydroxyproline averages of groups

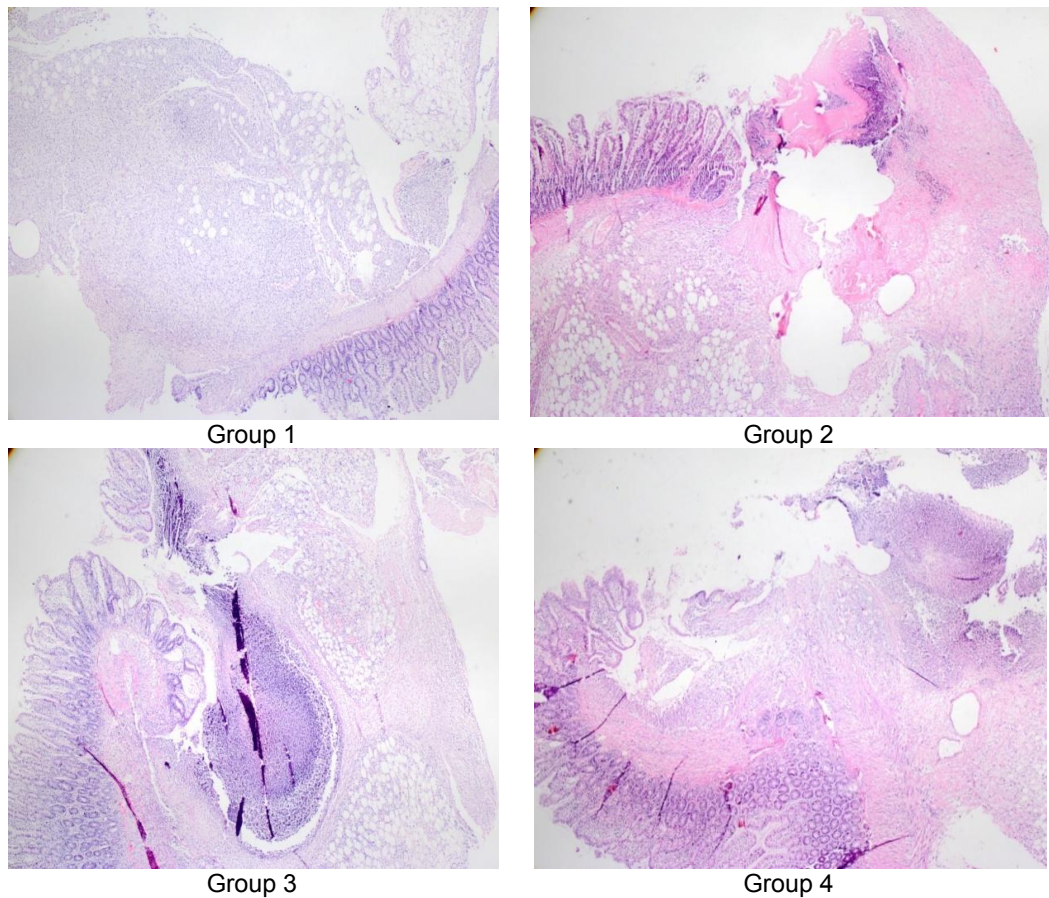


Fig. 5. Anastomosis line light microscopy images x80

4. DISCUSSION

IR injury is one of the major causes of AL [1-5]. Tadalafil prolongs the effects of NO by inhibition of PDE-5. As a result of this effect it regulates

microcirculation by inhibiting vasodilation and platelet aggregation in peripheral arteries and veins [10-13]. These effects of tadalafil suggest that it may be effective in preventing intestinal IR injury. In a study on the isolated rat heart, du Toit

et al. found that sildenafil reduced the size of the infarction and increased reperfusion function. In the ischemic heart, the protective effects of sildenafil are directed by increased levels of cyclic guanosine monophosphate (cGMP) [24-26]. Kaya et al. found that Tadalafil had positive effects on anastomotic healing in the ischemic small intestine in rats [6]. Zhang et al. in their experimental study on functional return after embolic stroke in rats showed that in rats after stroke, sildenafil can accelerate recovery of neurological function. Cortical cGMP levels were increased with the administration of sildenafil and progress was made in neurological recovery with increased angiogenesis and synaptogenesis [27]. In a study by Pasma et al., rats after IR were sacrificed on the three and fifth days and found significantly different bursting pressures and hydroxyproline levels on both the three and fifth days compared to the control group [28]. Hasanoglu et al. looked at bursting pressure and hydroxyproline levels on three and seventh days, but found no difference between three and seventh days, even though there was a significant difference in the control group [29]. Uzun et al. In their work; showed that sildenafil citrate has positive effects on oxidative stress in the ischemic anastomotic wound healing via NO pathway. At the same time, sildenafil supports wound healing more than normal anastomosis in ischemic anastomosis and this has been demonstrated by histopathological examinations [30]. In our study, similar to the study of Kaya et al. and Hasanoglu et al., anastomosis burst pressures were higher in the group receiving normal anastomosis + Tadalafil, but no statistical significance was found ($p: 0.24$). However, in the IR anastomosis + Tadalafil group, the anastomose bursting pressure was significantly higher than in the control group ($p: 0.003$). Hydroxyproline levels were high in the normal anastomosis + tadalafil group in contrast to the studies carried out by Hasanoglu et al., but no statistical difference was found (0.084). In contrast, IR + tadalafil was significantly higher in the group given. From this, it appears that tadalafil contributes more to wound healing in tissue damaged by IR than it does to wound healing in normal tissue. Although Hasanoglu et al. showed that wound healing was better in the group receiving sildenafil in their study, no significant difference was found in the histopathological examination in our study, as in the studies of Kaya et al. But in groups receiving tadalafil, the signs of regeneration were more pronounced. The reason we were not able to detect a difference histopathologically may be

that the optimal indicators of wound healing became apparent histopathologically after the fifth day of postoperative [31].

5. CONCLUSION

In summary; although the effect of tadalafil could not be demonstrated histopathologically, it was concluded that by increasing the amount of collagen in the anastomosis area and with a positive change in burst pressure values, it has positive effects on small bowel anastomosis healing after intestinal IR. We think that these positive effects are realized by increasing the NO amount.

CONSENT

It is not applicable.

ETHICAL APPROVAL

This study was carried out in Ege University Faculty of Medicine Experimental Research Laboratory with the compliance decision of Celal Bayar University Faculty of Medicine Scientific Research Animal Ethics Committee dated 16/05/2020 numbered 77.637.435.

COMPETING INTERESTS

Authors have declared that no competing interests exist.

REFERENCES

1. Woong BJ, Koo YH, Jung MK. Mechanical bowel preparation does not affect clinical severity of anastomotic leakage in rectal cancer surgery. *World J Surg.* 2017;41(5): 1366-1374. DOI: 10.1007/s00268-016-3839-9
2. Kuzu MA, Aslar AK, Mahmoud H, et al. Factors affecting the clinical outcome of primary resection for malignant colonic obstruction: Multivariate analysis. *Colorectal Disease.* 2003;5:91-91.
3. Nesbakken A, Nygaard K, Lunde OC, Blucher J, Gjertsen O, et al. Anastomotic leak following mesorectal excision for rectal cancer: True incidence and diagnostic challenges. *Colorectal Dis.* 2005;7(6):576-581. DOI: 10.1111/j.1463-1318.2005.00870.x

4. McDermott FD, Heeney A, Kelly ME, Steele RJ, et al. Systematic review of postoperative, intraoperative and postoperative risk factors for colorectal anastomotic leaks. *Br J Surg*. 2015;102(5): 462-479.
DOI: 10.1002/bjs.9697
5. Kuzu MA, Köksoy C, Kale IT, Tanik A, Terzi C, Elhan AH. Reperfusion injury delays healing of intestinal anastomosis in a rat. *Am J of Surgery*. 1998;176:348-351.
6. Kaya Y, Coskun T, Ayhan S, Kara E, Sakarya A, et al. The effect of Tadalafil on anastomotic healing in ischemic small intestine in rats. *Surg Today*. 2010;(40): 555-560.
DOI: 10.1007/s00595-010-4229-9
7. Megison SM, Horton JW, Chao H, Walker PB. A new model for intestinal ischemia in the rat. *J Surg Res*. 1990;49:168-173.
DOI: 10.1016/0022-4804(90)90257-3
8. Wu MY, Yiang GT, Liao WT, Tsai AP, Cheng PW, et al. Current mechanistic concepts in ischemia and reperfusion injury. *Cell Physiol Biochem*. 2018;46(4): 1650-1667.
DOI: 10.1159/000489241
9. Saidi RF, Kenari SK. Liver ischemia/reperfusion injury: An overview. *J Invest Surg*. 2014;27(6):366-379.
DOI: 10.3109/08941939.2014.932473
10. Gonzalez LM, Moeser AJ, Blikslager AT. Animal models of ischemia-reperfusion-induced intestinal injury: Progress and promise for translational research. *Am J Physiol Gastrointest Liver Physiol*. 2015; 308(2):63-75.
DOI: 10.1152/ajpgi.0012.2013
11. Grace PA. Ischaemia-reperfusion injury. *British J of Surgery*. 1994;81:637-647.
DOI: 10.1002/bjs.1800810504
12. Zimmerman BJ, Granger DN. Reperfusion injury. *Surgical Clinics of North America*. 1992;72:65-83.
DOI: 10.1016/s0039-6109(16)45628-8
13. Lefer AM., Lefer DJ. Pharmacology of the endothelium in ischemia reperfusion and circulatory shock. *Annu Rev Pharmacol Toxicol*. 1993;33:71-90.
DOI: 10.1146/annurev.pa.33.040193.000443
14. Brock GB, McMahon CG, Chen KK, Costigan T, Shen W, et al. Efficacy and safety of tadalafil for the treatment of erectile dysfunction: Results of integrated analyses. *J Urol*. 2002;168:1332-6.
DOI: 10.1097/01.ju.0000028041.27703.da
15. Galie N, Brundage BH, Ghofrani HA, Oudiz RJ, Simonneau G, et al. Tadalafil therapy for pulmonary arterial hypertension. *Circulation*. 2009;119:2894-903.
DOI: 10.1161/CIRCULATIONAHA.108.839274
16. Gudmundsdottir IJ, McRobbie SJ, Robinson SD, Newby DE, Megson IL. Sildenafil potentiates nitric oxide mediated inhibition of human platelet aggregation. *Biochemical and Biophysical Research Communications*. 2005;337:382-385.
DOI: 10.07/s00384-002-0392-9
17. Colle I, De Vriese, Van Vlierberghe H, Lameire NH, De Vos M. Systemic and splanchnic haemodynamic effects of sildenafil in an in vivo animal model of cirrhosis support for a risk in cirrhotic patients. *Liver International*. 2004;24:63-68.
DOI: 10.1111/j.1478-3231.2004.00892.x
18. Sharma R. Novel phosphodiesterase-5 inhibitors: Current indications and future directions. *Indian J Med Sci*. 2007;61(12): 667-79.
DOI: 10.4103/0019-5359.37789
19. Mansson P, Zhang XW, Jeppsson B, Thorlacius H. Anastomotic healing in the rat colon: Comparison between a radiological method, breaking strength and bursting pressure. *Int J Colorectal Dis*. 2002;17:420-425.
DOI: 10.1007/s00384-002-0392-9
20. Akyuz C, Yasar NF, Uzun O, Peker KD, Sunamak O, et al. Effect of melatonin on colonic anastomosis healing following chemotherapy in rats. *Singapore Med J*. 2018;59(10):545-549.
DOI: 10.11622/smedj.2018035
21. Bergman I, Loxley R. Two improved and simplified methods for spectrophotometric determination of hydroxyprolin. *Anal. Chem*. 1964;35:1961-1964.
22. Ehrlich HP, Tarver H, Hunt TK. Effects of vitamin A and glucocorticoids upon inflammation and collagen synthesis. *Ann Surg*. 1973;177:222-7.
DOI: 10.1097/00000658-197302000-00017
23. Ayten R, Çetinkaya Z, Girgin M, Özeran İ, Üstündağ B, et al. The effects of intraperitoneal sildenafil administration on healing of left colonic anastomoses and intraabdominal adhesion formation in the presence of intraabdominal infection. *Dis Colon Rectum*. 2008;51(12): 1837-41.
DOI: 10.1007/s10350-008-9398-x

24. Li Z, Xi X, Gu M, et al. A Stimulatory role for cGMP-dependent protein kinase in platelet activation. *Cell*. 2003;112:77-86. DOI: 10.1016/s0092-8674(02)01254-0
25. Bischoff E. Potency, selectivity, and consequences of nonselectivity of PDE inhibition. *Int J Import Res*. 2004;16:11-14. DOI: 10.1038/sj.ijir.3901208
26. du Toit EF, Rossouw E, Salie R, Opie LH, Lochner A. Effect of sildenafil on reperfusion function, infarct size, and cyclic nucleotide levels in the isolated rat heart model. *Cardiovasc Drugs Ther*. 2005;19:23-31. DOI: 10.1007/s10557-005-6894-2
27. Zhang L, Zhang RL, Wang Y, Zhang C, Zhang ZG, et al. Functional recovery in aged and young rats after embolic stroke: Treatment with a phosphodiesterase type 5 inhibitor. *Stroke*. 2005;36:847-52. DOI: 10.1161/01.STR.0000158923.19956.73
28. Posma LAE, Bleichrodt RP, van Goor H, Hendriks T. Ischemia and prolonged reperfusion before anastomotic construction do not reduce wound strength in the rat intestine. *Surgery*. 2006;139:671-7. DOI: 10.1016/j.surg.2005.10.014
29. Hasanoğlu A, Erkan S, Temel S, Urhan MK, Güler O. Effect of sildenafil citrate on healing of colonic anastomoses. *Turkish Medical Journal*. 2007;1:66-75.
30. Uzun H, Konukoğlu D, Nuri MK, Ersoy EY, Özçevik S, et al. The effects of sildenafil citrate on Ischemic colonic anastomotic healing in rats: Its relationship between nitric oxide and oxidative stress. *World J Surg*. 2008;32:2107-2113. DOI: 10.1007/s00268-008-9661-2
31. Attard JA, Raval MJ, Martin GR, et al. The effects of systemic hypoxia on colon anastomotic healing: An animal model. *Dis Colon Rectum*. 2005;48:1460-1470. DOI: 10.1007/s10350-005-0047-3

© 2020 Mutlu et al.; This is an Open Access article distributed under the terms of the Creative Commons Attribution License (<http://creativecommons.org/licenses/by/4.0>), which permits unrestricted use, distribution, and reproduction in any medium, provided the original work is properly cited.

Peer-review history:

The peer review history for this paper can be accessed here:
<http://www.sdiarticle4.com/review-history/60902>